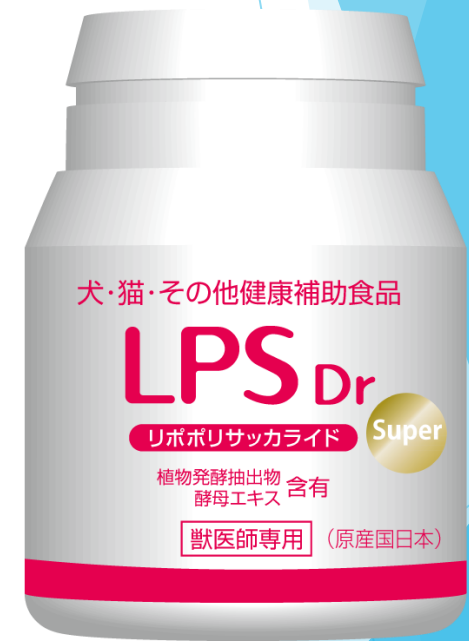

Case report of using LPS Dr in overseas small animals

Scarecrow Incorporated



Introduction

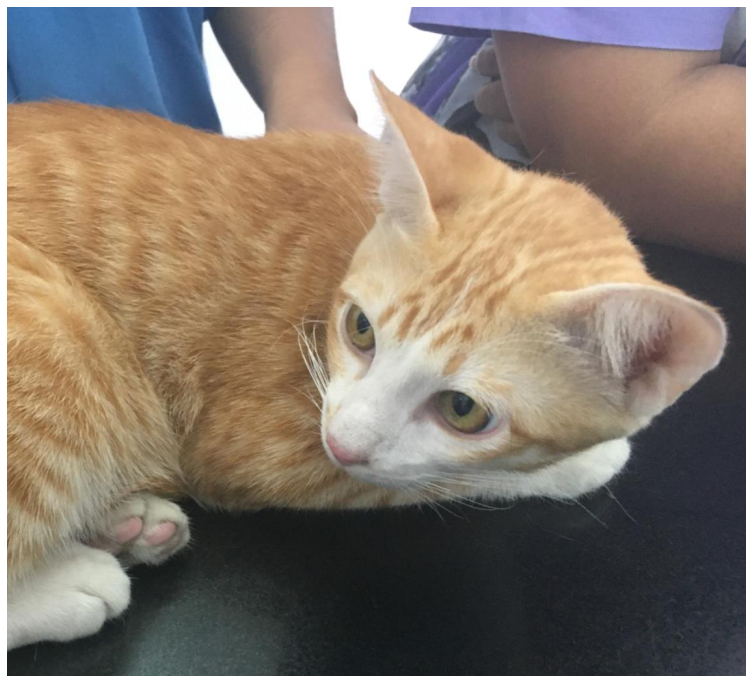▶ Case 1

Study case : Feline

Male

Domestic Short Hair

7 month-old



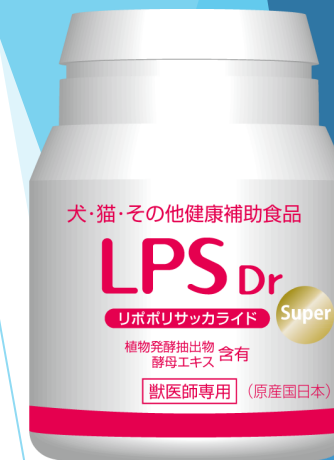▶ Case 2

Study case : Feline

Female

Domestic Short Hair

7 years old



Introduction : Dermatophytosis

- ▶ Zoonosis
- ▶ The infection of *M. canis* and *M. gypseum* and *T. mentagrophytes*
- ▶ **Symptoms** : Hair loss
- ▶ **Diagnosis** : Fungal culture and Blood examination
- ▶ **Treatment** : External Medicine and Oral Administration Medicine

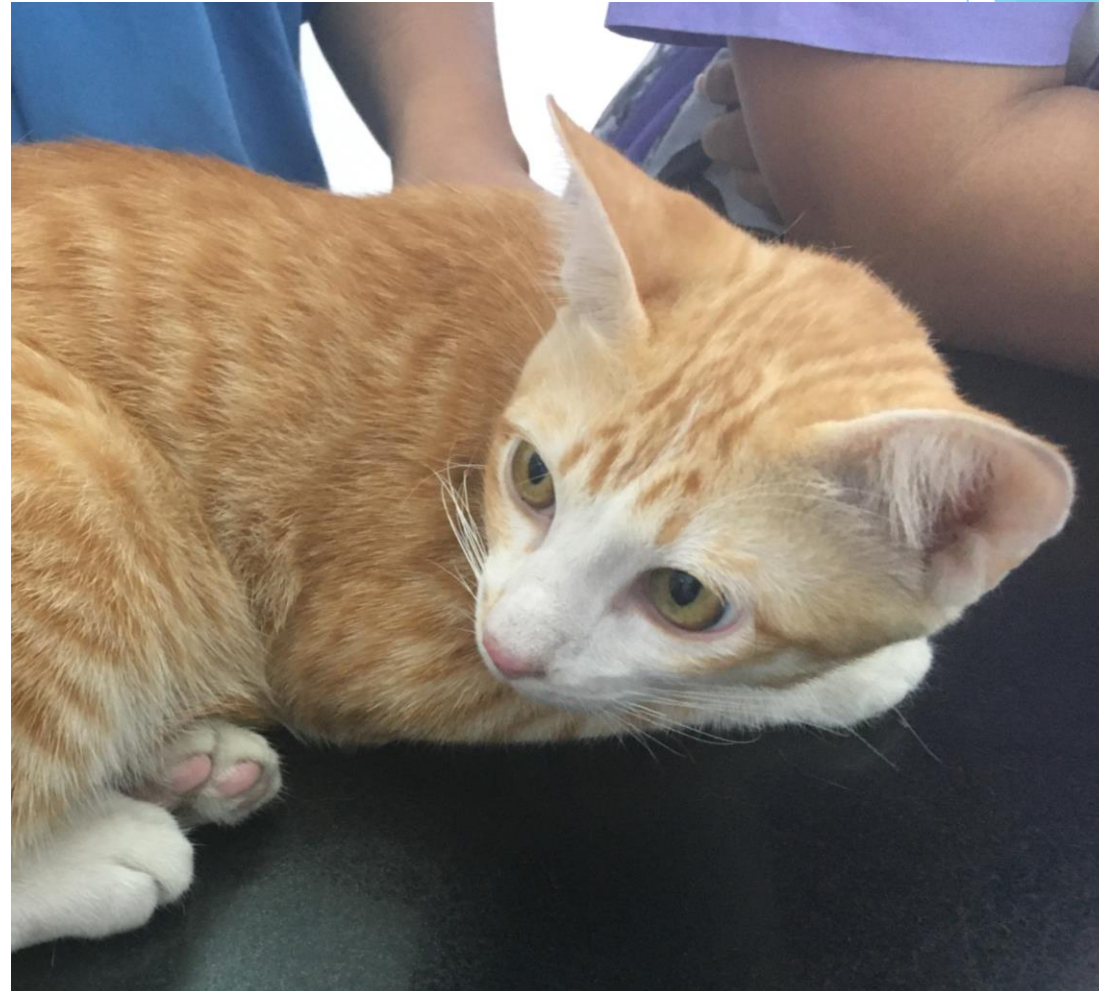Case 1

▶ Pet Information

- ▶ Domestic Short Hair
- ▶ 7-month old
- ▶ Male
- ▶ Weight 3.3 kg

▶ Physical Examination

- ▶ Itchy
- ▶ Atopic dermatitis
- ▶ Erythema



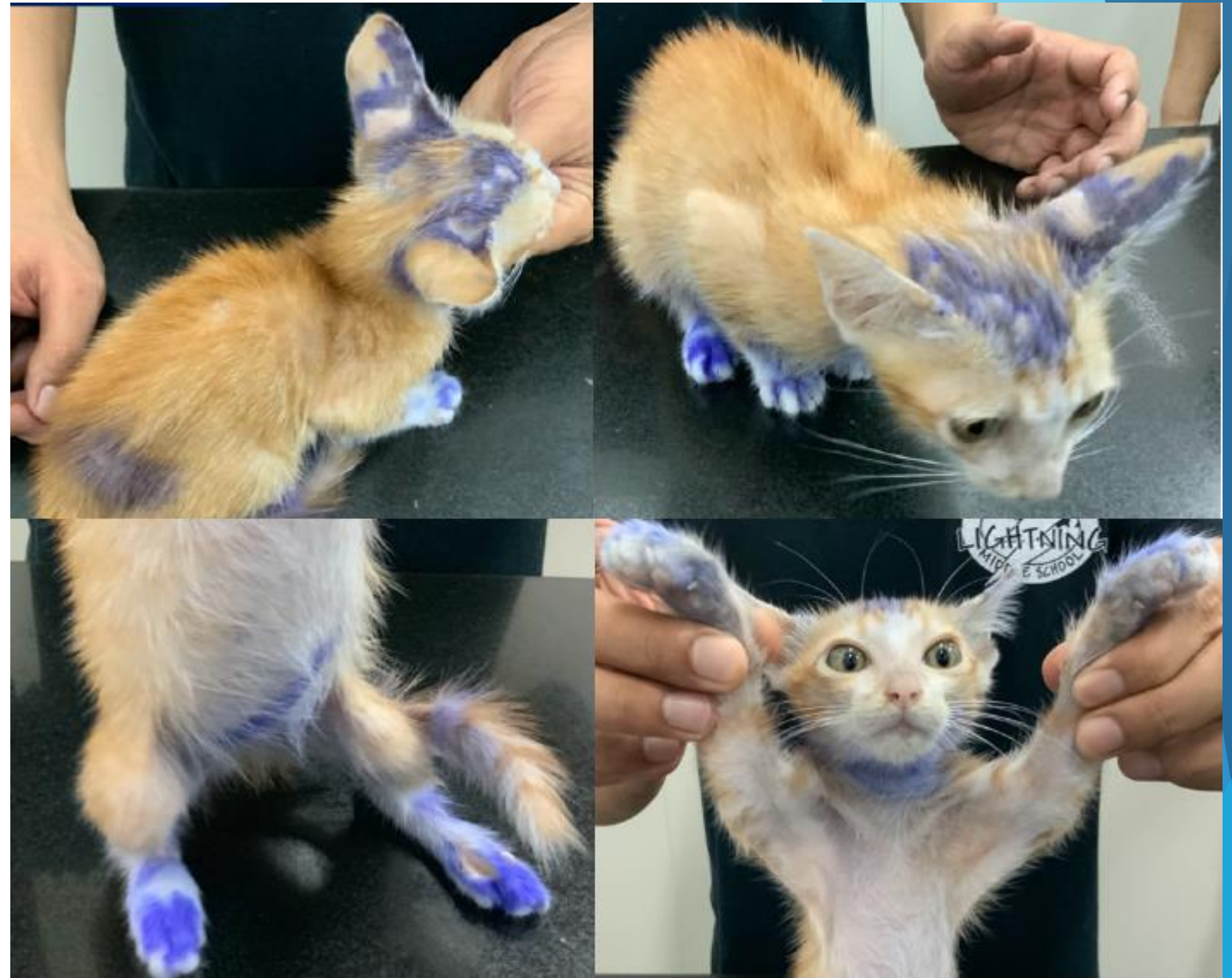Case 1 : Day0

▶ Pet Information

- ▶ Domestic Short Hair
- ▶ 7 -month old
- ▶ Male
- ▶ Weight 3.3 kg

▶ Physical Examination

- ▶ Itchy
- ▶ Atopecia
- ▶ Erythema

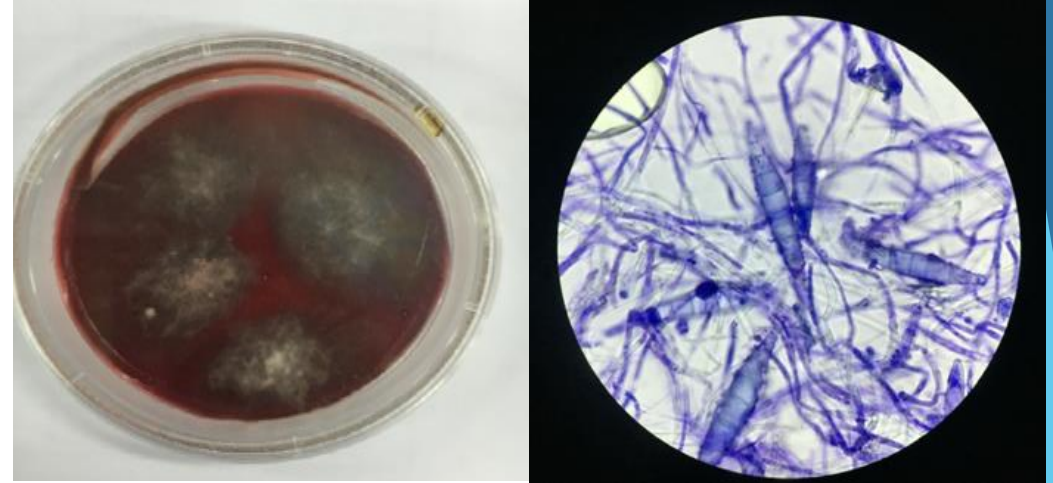



VAS (Itching Evaluation Scale)

0	1	2	3	4	5	6	7	8	9	10
No pain					●					Severe pain

Case 1 : Diagnosis

Fungal culture



(*Microsporum canis*)

Dermatophytosis
Generalized lesion



Treatment



Case 1 : Diagnosis


Fungal culture



Dermatophytosis
Generalized lesion







Treatment



LPS Dr 1 tablet/day
Funginox solution
Medical Shampoo



Case 1 : Follow-up and Treatment

	Day0	Day 45	Day 75	Day 105
				
VAS	5/10	0/10	0/10	0/10
Treatment	<ul style="list-style-type: none"> • Funginox solution • Medical Shampoo 	Medical Shampoo		
LPS Dr	LPS Dr 1tablet/day			
Fungal culture	+ M. Canis	-	-	



Case 2

▶ Pet Information

- ▶ Domestic Short hair
- ▶ 7 years old
- ▶ Female
- ▶ Ovariohysterectomy
- ▶ Weight 3.8 kg

▶ Physical Examination

- ▶ Atopecia
- ▶ Erythema



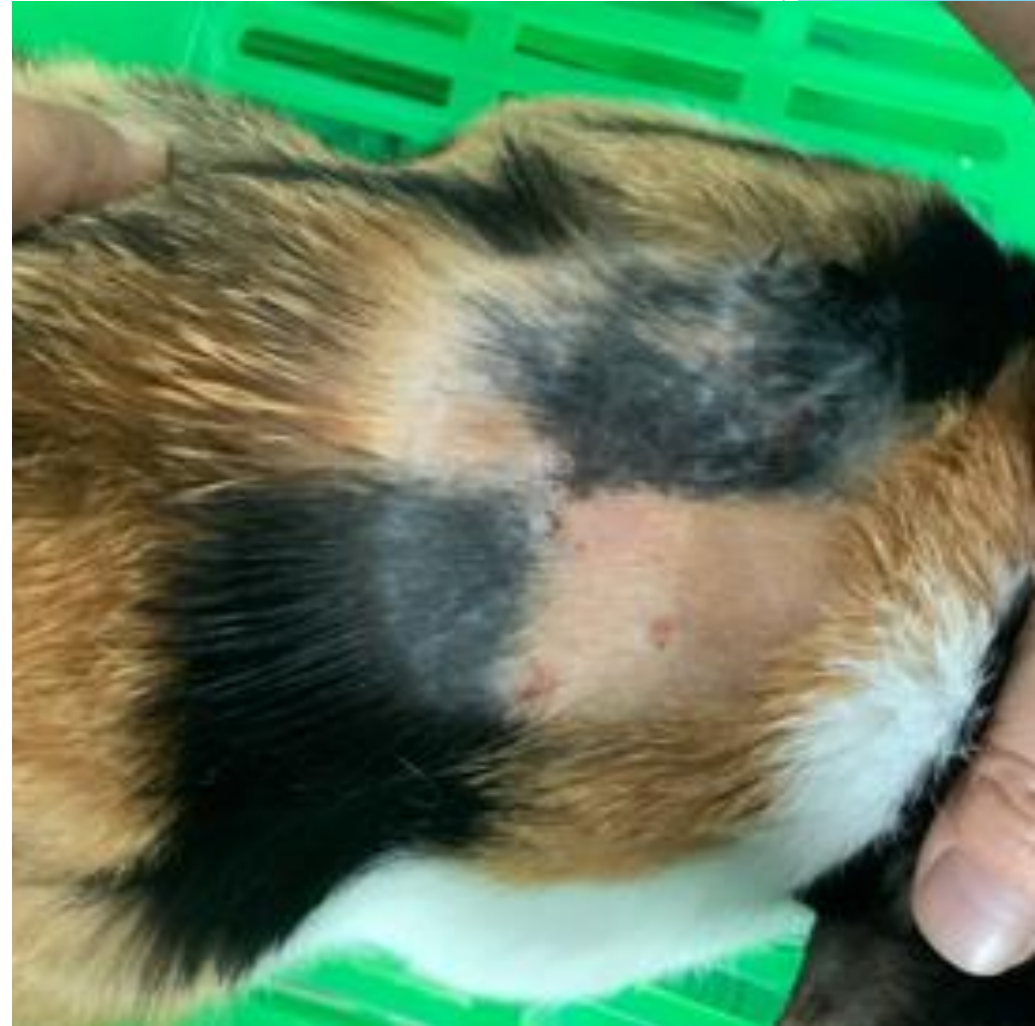
Case 2 : Day0

▶ Pet Information

- ▶ Domestic Short hair
- ▶ 7 years old
- ▶ Female
- ▶ Ovariohysterectomy
- ▶ Weight 3.8 kg

▶ Physical Examination

- ▶ Atopecia
- ▶ Erythema




VAS (Itching Evaluation Scale)

0	1	2	3	4	5	6	7	8	9	10
No pain					●					Severe pain

Case 2 : Diagnosis

Blood examination



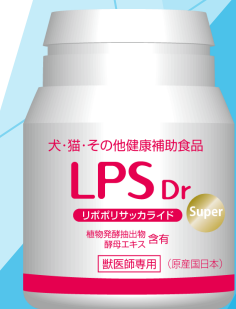Degenerative neutrophil
with intracellular cocci
bacteria



Fungal culture



Treatment

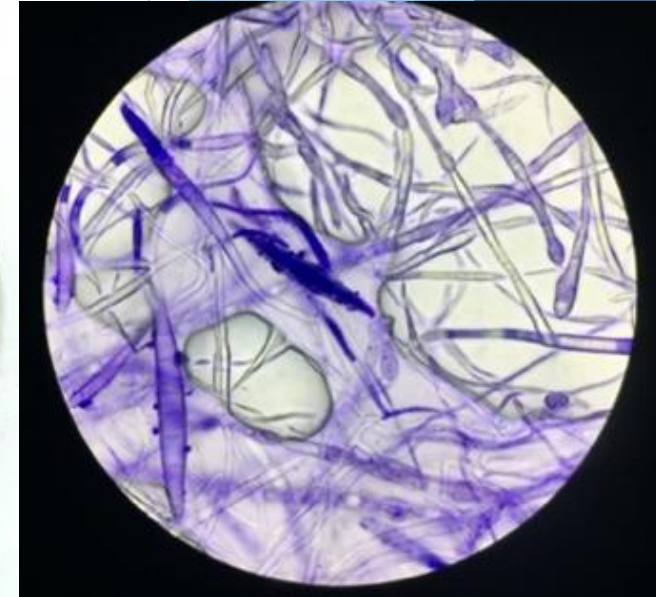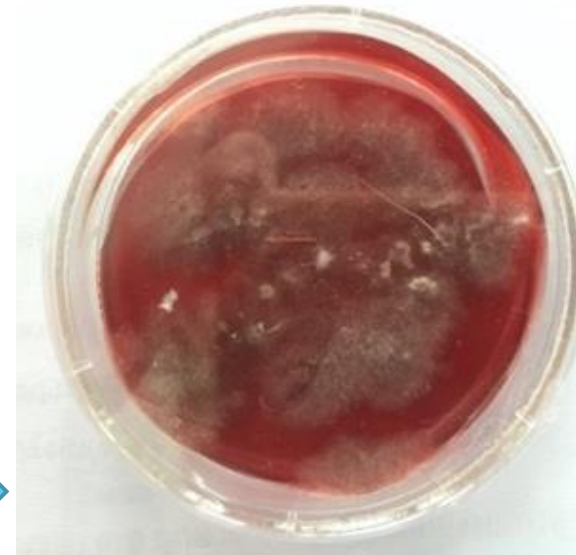
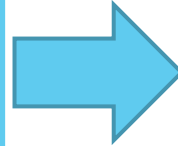


Case 2 : Diagnosis

Blood examination



Fungal culture



(*Microsporum canis*)

Treatment



Case 2 : Diagnosis


Blood examination



Fungal culture



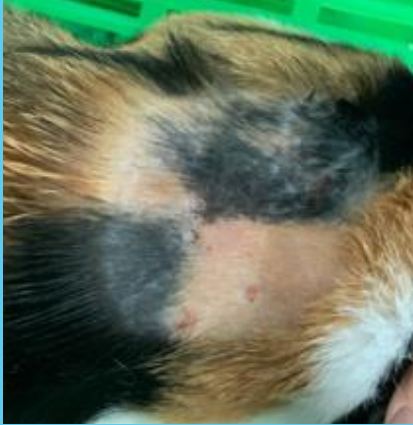


Treatment



LPS Dr 1tablet/day
Funginox Solution
Antibiotic



Case 2 : Follow-up and Treatment

	Day 0	Day 22	Day 53
			
VAS	5/10	0/10	0/10
Treatment	<ul style="list-style-type: none"> • Funginox solution • Antibiotic 		Funginox solution
LPS Dr	LPS Dr 1tablet/day		
Fungal culture	+ M. Canis	-	-



Conclusion

- ▶ According to the results from Case 1 and Case 2, LPS Dr had been able to use in combination with external medicine, oral administration medicine and medical shampoo to treat dermatophytosis in Feline.



Introduction : Canine Atopic Dermatitis

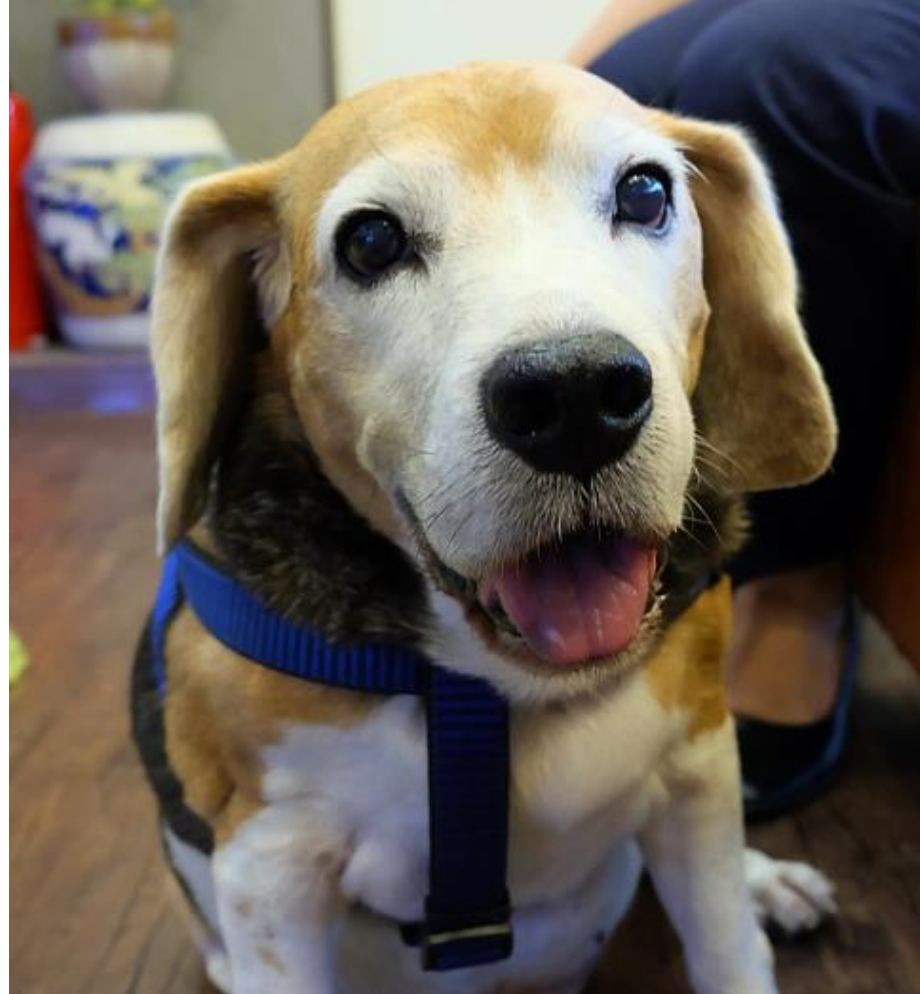▶ Case 3

Study Case : Canine

Male

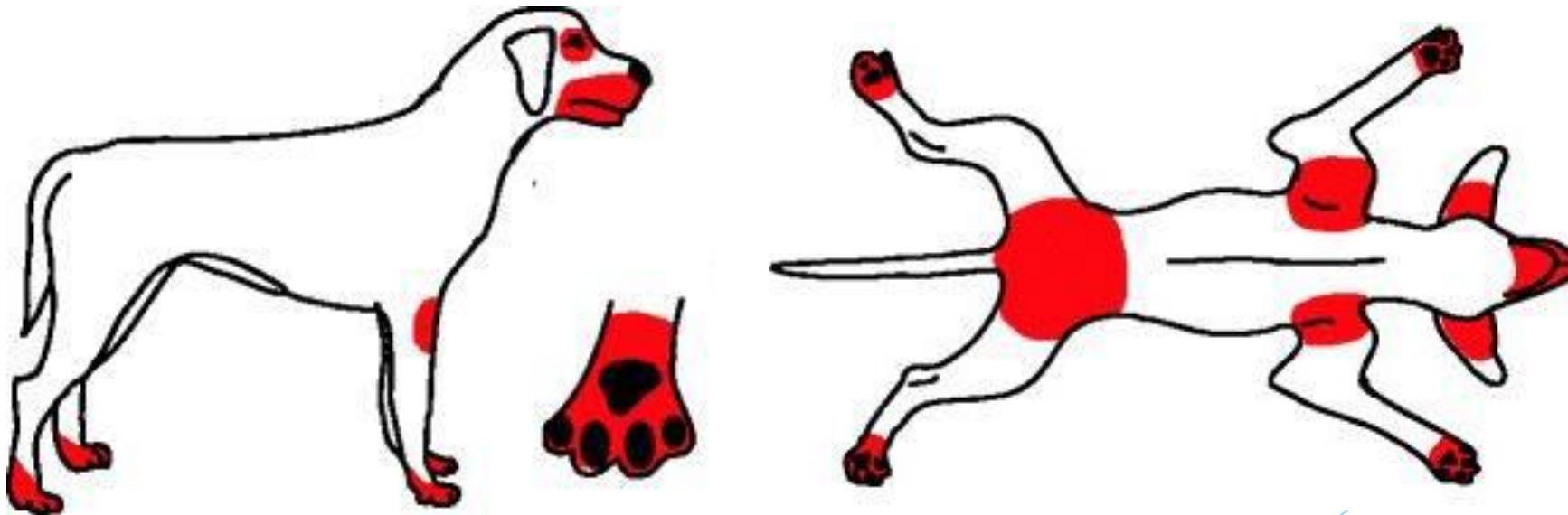
Beagle

8 years old



Introduction : Canine Atopic Dermatitis

- ▶ Genetically predisposed
- ▶ Associated most with IgE antibody
- ▶ Face, ear pinnae, axillae, inguinal area, perineal area and distal extremities are most commonly affected



Case 3

▶ Pet Information

- ▶ Beagle
- ▶ 8 years old
- ▶ Castrated Male
- ▶ Weight 12.4 kg

▶ Physical examination

- ▶ Diffuse papule at inguinal area
- ▶ Pododermatitis
- ▶ Erythema of both ear pinna with brown ear wax




Case 3 : Diagnosis

Allergen specific IgE test

Biopsy

Treatment




Case 3 : Diagnosis

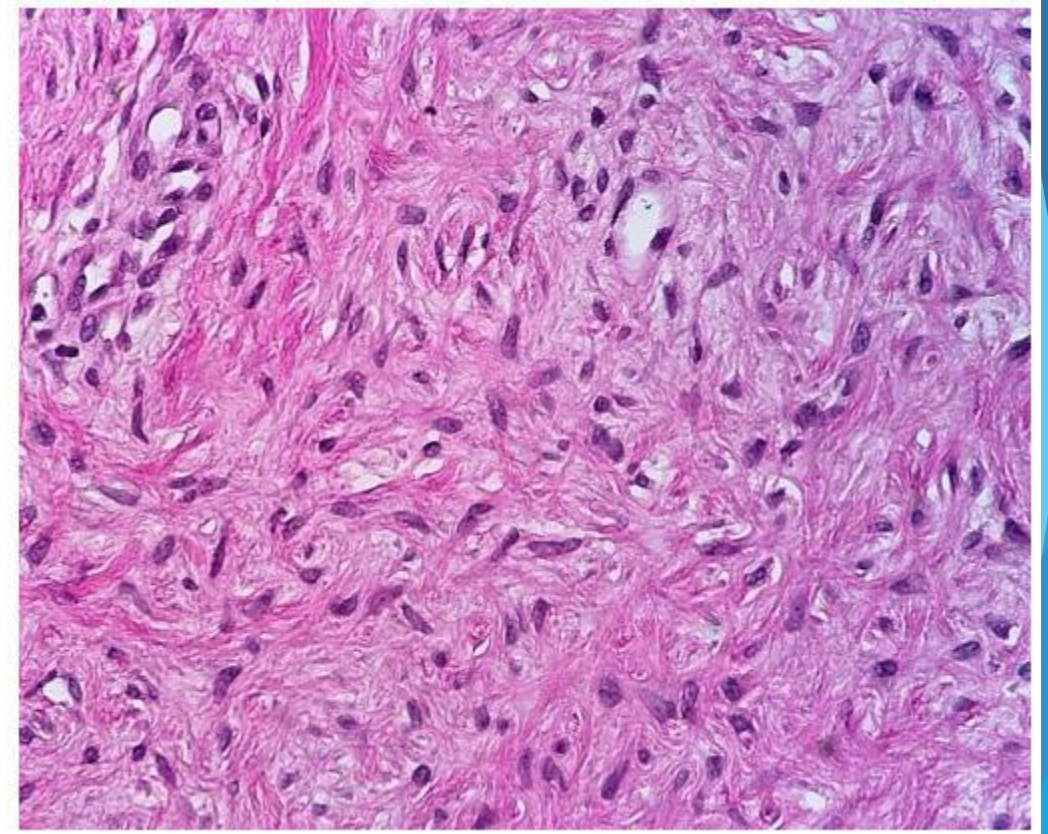
Allergen specific IgE
test



Biopsy



Treatment



(Fibromatous epulis)

Case 3 : Diagnosis


Allergen specific IgE
test



Biopsy





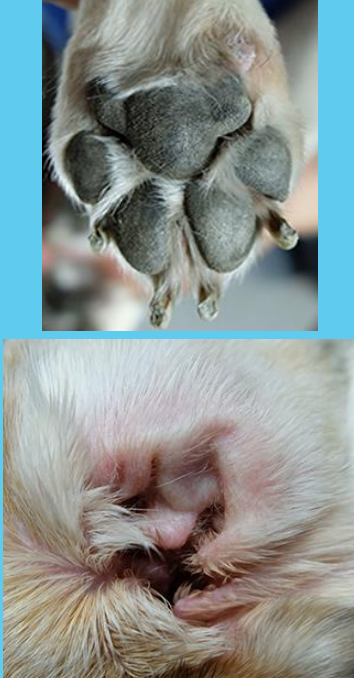
Treatment



LPS Dr 3tablets/day
Cyclosporine
Hydroxyzine dihydrochloride



Case 3 : Follow-up and Treatment

	2015	2016	2017	2018
				
VAS	6/10	4/10	2/10	2/10
Treatment	Cyclosporine Hydroxyzine dihydrochloride		Cyclosporine	-
LPS Dr	-	-	LPS Dr 3tablets/day	



Conclusion

- ▶ LPS had been able to use as alternative treatment to manage Canine atopic dermatitis without any side effects.



Thank you for your attention